

# Efficacy and Safety of High-Intensity, High-Frequency, Parallel Ultrasound Beams for Fine Lines and Wrinkles

Jordan V. Wang, MD, MBE, MBA,\* Georgina Ferzli, MD,\* Hana Jeon, MD,\* Roy G. Geronemus, MD,\*† and Arielle Kauvar, MD†‡

**BACKGROUND** Ultrasound energy has been used for cutaneous rejuvenation, including treatment of fine lines and wrinkles. Ultrasound waves of high intensity can induce thermal injury in the dermis, which causes tissue coagulation and remodeling.

**OBJECTIVE** To examine the safety and utility of a novel ultrasound device that uses high-intensity, high-frequency, parallel ultrasound beams to improve fine lines and wrinkles of the face and neck.

**MATERIALS AND METHODS** A prospective, multicenter, clinical study investigated the utility of this novel ultrasound device to improve fine lines and wrinkles. Sixty subjects were enrolled for single treatment to the face and neck.

**RESULTS** Fifty-eight subjects completed the study. The mean age was 58 years, and 87.9% were women. Fitzpatrick skin Types I to VI were represented. Assessments compared 12-week follow-up with baseline. Two blinded reviewers agreed in identifying pretreatment and post-treatment photographs for 78% of subjects. There was significant improvement of 1 to 3 Fitzpatrick Wrinkle and Elastosis Scale units in 86% of subjects. For investigator global improvement scores, 88% of subjects had improvement. Overall, 72% of subjects noted improvement, and the majority were satisfied. There were no device-related adverse events.

**CONCLUSION** Treatment with a novel ultrasound device that uses high-intensity, high-frequency, parallel ultrasound beams safely improved the clinical appearance of fine lines and wrinkles of the face and neck.

Facial aging can be due to intrinsic processes and outside influences, such as environmental stressors. Exposure to ultraviolet radiation, pollution, and harmful chemicals can all cause repetitive and chronic cellular injury, which can affect epidermal and dermal cells. Over time, these small insults can accumulate and negatively affect normal cellular function and processes.<sup>1–5</sup> As the skin ages, it can begin to lose its smoothness, firmness, hydration, and elasticity, which can be associated with the loss of optimal cellular structure and the breakdown of collagen and elastin.

Aging facial skin is associated with fine lines and wrinkles as well as sagging and laxity. These are common complaints of cosmetic patients, who often seek treatment. Currently, several minimal and noninvasive treatment modalities have been used to treat fine lines and wrinkles and to tighten lax skin.<sup>6–8</sup> The goals of these treatments are to improve the skin's structure by increasing the amount of collagen and elastin within. The underlying mechanism of action for many noninvasive treatments relies on the creation of controlled thermal damage

in the dermis and subdermal areas while minimizing epidermal injury.<sup>9</sup> This stimulates neocollagenesis and ne elastogenesis, which ultimately leads to collagen remodeling that can achieve a more youthful appearance.

In recent years, ultrasound energy has been used for cutaneous rejuvenation.<sup>10–12</sup> With this technology, ultrasonic waves are generated by a transducer using a piezoelectric crystal that converts electrical energy to mechanical energy. Ultrasound waves of high intensity can be used to induce thermal injury localized to the dermis and cause tissue coagulation and subsequent remodeling. A key benefit of using ultrasound energy is that its absorption is not dependent on a particular skin chromophore, which makes its use safe and consistent in all skin phototypes. Instead, the controlled injury is a function of the energy absorbed by the tissue without regard to tissue variations. The injury can be safely contained within the targeted zone. Without epidermal injury, there can also be limited downtime.

The first-generation ultrasound devices used high-intensity focused ultrasound beams. Although this technology can be effective, treatment delivery requires real-time ultrasound visualization and is operator dependent. A new-generation ultrasound device has recently been introduced with the goal of improving on earlier technology. This novel ultrasound device uses high-intensity, high-frequency, parallel ultrasound beams that bypass the epidermal layer and directs the thermal damage to depths of 0.5 to 2 mm while avoiding injury to deeper anatomic structures.

From the \*Laser & Skin Surgery Center of New York, New York, New York; †The Ronald O Perleman Department of Dermatology, New York University Langone Health, New York, New York; ‡New York Laser & Skin Care, New York, New York Supported by Sofwave.

R. G. Geronemus and A. Kauvar are on the advisory board of Sofwave. The remaining authors have indicated no significant interest with commercial supporters.

Address correspondence and reprint requests to: Jordan V. Wang, MD, MBE, MBA, Laser & Skin Surgery Center of New York, 317 E 34th Street, 6th Floor Research Department, New York, NY 10016, or e-mail: djordanwang@gmail.com  
<http://dx.doi.org/10.1097/DSS.0000000000003208>

The authors hypothesized that treatment with this novel ultrasound device can safely improve the clinical appearance of fine lines and wrinkles of the face and neck. The authors performed an open-label prospective study to assess the efficacy and safety of this treatment.

## Materials and Methods

Sixty healthy subjects who were 35 to 70 years old and seeking treatment for facial lines and wrinkles were enrolled at 2 clinical sites, which included Laser & Skin Surgery Center of New York, New York, NY (LSSCNY), and New York Laser & Skin Care, New York, NY (NYLSC). This study was approved by an independent institutional review board (IRB). Informed consent was obtained from subjects.

Subjects were excluded if they had active systemic or local infections; active local skin disease that may alter wound healing; severe solar elastosis; history of smoking in the past 10 years; history of chronic drug or alcohol abuse; excessive subcutaneous fat on the cheeks; significant facial scarring; severe or cystic facial acne; metal stent or implant in the face; ongoing use of psychiatric medication; recent history of cosmetic treatments in the face, including skin-tightening procedure within the past 1 year, injectable filler within the past 1 year, botulinum toxin in the lower face within the past 6 months, ablative or nonablative resurfacing laser treatment or light treatment within the past 6 months, dermabrasion or deep facial peels within the past 6 months, and face-lift, blepharoplasty, or brow lift within the past 6 months; history of isotretinoin use within the past 6 months; history of antiplatelet or anticoagulant use within the past 2 weeks; and if they were pregnant or planning to become pregnant, having given birth less than 3 months ago, and/or breastfeeding.

Each subject received a single treatment to the full face and neck using a novel ultrasound device that uses high-intensity, high-frequency, parallel ultrasound beams (Sofwave, Yokneam, Israel). Before treatment, subjects were offered the option of a topical anesthetic (lidocaine 2.5%/prilocaine 2.5% at LSSCNY and lidocaine 23%/tetracaine 7% at NYLSC) applied to the treatment area for 45 minutes and intramuscular injection of a nonsteroidal anti-inflammatory agent (NSAID) (ketorolac). The treatment area was cleansed and allowed to dry completely. Immediately before treatment, a thin layer of ultrasound gel was applied to the skin. The entire facial and upper neck areas were treated, including the forehead, cheeks, and neck. Most subjects (84.5%) had 2 passes to the entire treatment area, whereas others had either 1 or 3 passes to the treatment areas based on immediate tissue response and subject comfort level. After treatment, the ultrasound gel was removed with water-soaked gauze.

Digital photographs were standardized with respect to subject positioning and ambient lighting. Photographs were taken at baseline before treatment, at 7 days post-treatment, and at 12 weeks post-treatment. Immediately after treatment, subjects were asked to rank their pain level using Visual Analog Scale (10-point scale). The Global Aesthetic Improvement Scale (GAIS) (5-point scale) was used by

investigators and subjects to grade their clinical improvement from baseline at the 12-week follow-up visit. The Fitzpatrick Wrinkle and Elastosis Scale (9-point scale) was used by investigators at baseline and 12-week follow-up visit to grade subjects. This scale was also used by 2 independent and blinded evaluators to assess pretreatment and post-treatment photographs. Blinded reviewers were also instructed to correctly select pretreatment and post-treatment photographs, and their inter-rater agreement was measured. Subject satisfaction was assessed at the 12-week follow-up.

Adverse events were assessed throughout the study period. Questions utilizing Likert scale were analyzed using modified top-box scoring. Analysis was performed with subjects completing the entirety of the study. Descriptive statistics were performed.

## Results

### Subject Demographics

A total of 58 subjects completed the study (1 subject dropped out before the first treatment because of consent withdrawal; one subject dropped out after the treatment before follow-up because of noncompliance). The mean age was 58.0 years (R: 43–73 years). Of all subjects, 87.9% ( $n = 51$ ) were female. For Fitzpatrick skin type, 1.7% of subjects were Type I ( $n = 1$ ), 51.7% ( $n = 30$ ) were Type II, 31.0% ( $n = 18$ ) were Type III, 8.6% ( $n = 5$ ) were Type IV, 1.7% ( $n = 1$ ) were Type V, and 5.2% ( $n = 3$ ) were Type VI.

### Treatment Parameters

All subjects received treatment to their full face and neck. The mean pulse energy was 3.9 J (R: 2.8–5.0 J) for the cheeks, 3.9 J (R: 2.4–5.0 J) for the forehead, and 3.9 J (R: 2.8–5.0 J) for the neck. The mean number of pulses was 94 (R: 48–149) for the face and 55 (R: 18–97) for the neck.

### Clinical Rating

According to investigator GAIS, 87.9% ( $n = 51$ ) of subjects had improvement from baseline at the 12-week follow-up. The remaining subjects (12.1%;  $n = 7$ ) were rated to have no clinical change. No investigator rated the subjects to worsen. For subject GAIS, 72.4% ( $n = 42$ ) of subjects saw improvement at the 12-week follow-up. Of the remaining subjects, 25.9% ( $n = 15$ ) believed that they had no clinical change and only a single subject (1.7%) rated their condition to worsen.

For investigator rating of the Fitzpatrick Wrinkle and Elastosis Scale, 86.2% ( $n = 50$ ) of subjects had improvement from baseline at the 12-week follow-up. The remaining subjects (13.8%;  $n = 8$ ) were rated to have no clinical change. No investigator rated the subjects to worsen. Overall, 69.0% ( $n = 40$ ) of subjects had a 1-unit improvement, 15.5% ( $n = 9$ ) of subjects had a 2-unit improvement, and 1.7% ( $n = 1$ ) of subjects had a 3-unit improvement.

## Blinded Evaluator Rating

For photographic evaluation, 2 blinded and independent reviewers were in agreement in correctly identifying the pretreatment and post-treatment photographs for 77.6% ( $n = 45$ ) of subjects. For blinded evaluator ratings of the Fitzpatrick Wrinkle and Elastosis Scale, reviewers were in agreement in selecting post-treatment photographs that demonstrated at least a 1-unit improvement from baseline in 77.6% ( $n = 45$ ) of subjects.

## Subject Assessment

For pain management, subjects used either topical anesthesia (79.3%;  $n = 46$ ), topical anesthesia with intramuscular NSAID injection (13.8%;  $n = 8$ ), or neither (6.9%;  $n = 4$ ). The reported mean pain level was 7.5 ( $R: 2-10$ ). No subjects withdrew from the study because of discomfort or pain.

Of all subjects, the slight majority (58.6%;  $n = 34$ ) were satisfied at the 12-week follow-up, whereas another 25.9% ( $n = 15$ ) had no opinion. Only a small minority (15.5%;  $n = 9$ ) were dissatisfied. At the 12-week follow-up, most subjects (63.8%;  $n = 37$ ) agreed that they would undergo an additional treatment in the near future.

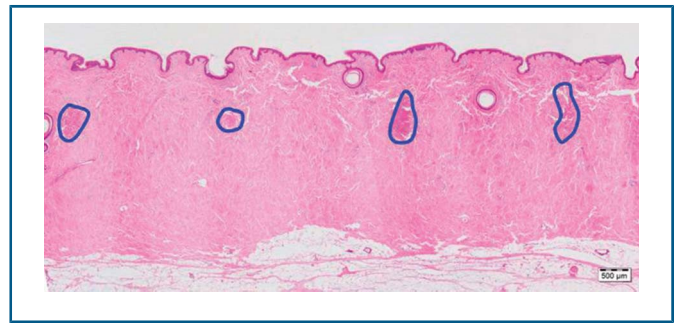
## Safety and Pain

During the study period, no device-related adverse events were reported by any subject. Only expected treatment effects were observed by subjects who completed the study, which included transient erythema and edema. After treatment, there were no cases of significant pain, tenderness, skin pigmentation, erosion, ulceration, or bruising.

## Discussion

Since the introduction of ultrasound technology to the field of medicine, it has been used in a wide variety of applications, including diagnostics, tumor ablation, and lithotripsy.<sup>13-16</sup> Its use has more recently expanded to aesthetics and includes body contouring, skin tightening, and treatment of fine lines and wrinkles. The mechanism underlying its skin tightening effects is based on the ability of ultrasonic waves to propagate through tissue and create thermal injury.<sup>17</sup> The acoustic waves vibrate the targeted tissue, which creates molecular friction that generates heat and coagulation. The healing process stimulates new collagen and elastin fibers, which are responsible for clinical tightening and the improvement of fine lines and wrinkles.

A novel ultrasound device was recently developed that uses Synchronous Ultrasound Parallel Beam Technology (SUPERB Technology, Sofwave, Yokneam, Israel), which the authors used in this study. This device generates high-intensity, high-frequency ultrasonic pulses that elevate dermal temperatures to cause controlled isolated areas of thermal damage. The handpiece contains 7 parallel transducers that are in direct contact with the skin surface and can deliver energy to the mid dermis, with the coagulation zone depth ranging from 0.5 to 2 mm and centered at 1.5 mm (Figure 1). The size of the thermal zones can vary based on energy, but they can span approximately

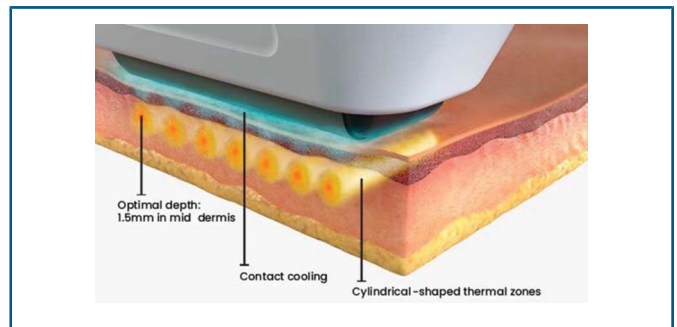


**Figure 1.** Histologic sample of coagulation zones at progressively higher energies from a novel ultrasound device that uses high-intensity, high-frequency, parallel ultrasound beams.

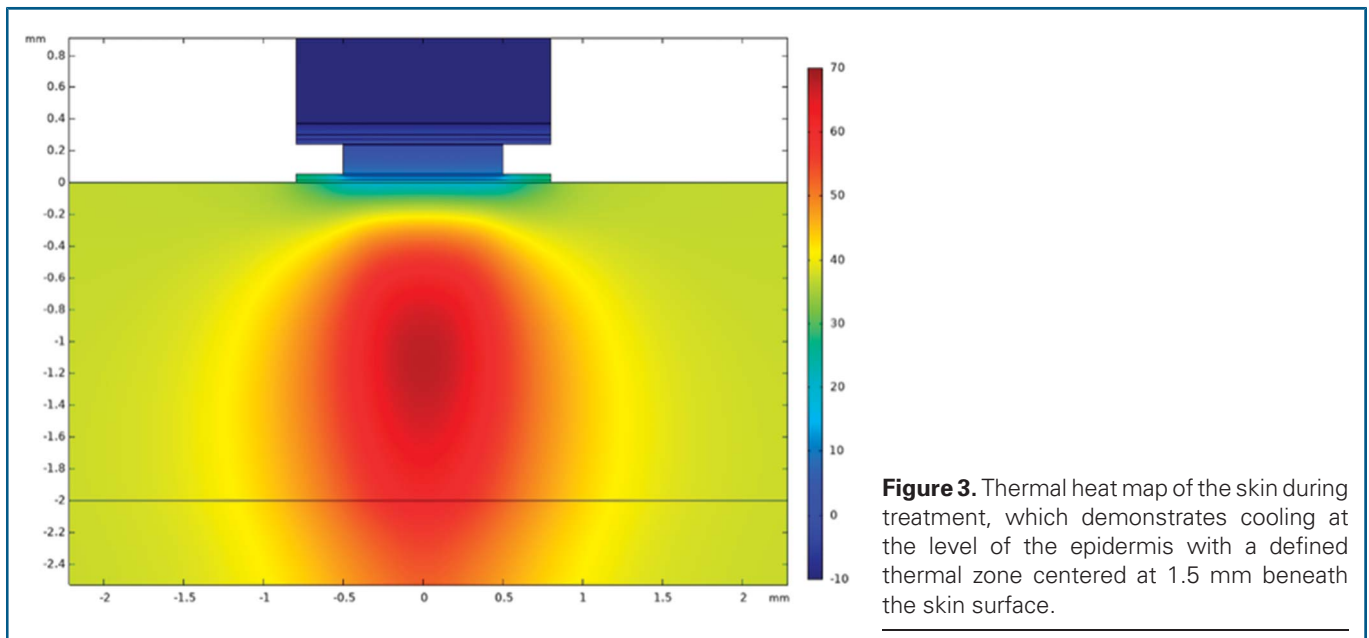
500 to 1,500  $\mu\text{m}$  in depth. Because all the 7 transducers are triggered with each pulse, there is a high area of coverage, which translates to a total treatment time of 30 to 45 minutes for the entire face and neck. Based on in vivo histologic analysis, 2 passes over the treatment area with 50% overlap covers approximately 28% of the mid dermal layer. This technology does not require real-time ultrasound visualization because the thermal injury remains at a fixed depth that is superficial to the bone and neurovascular bundles.

As the parallel ultrasound beams propagate through the tissue, an array of volumetric, cylindrical-shaped thermal zones is created (Figure 2). These coagulated columns lie parallel to the skin surface along the long axis of the transducers. The parallel positioning of the coagulated columns of tissue relative to the skin surface produces a high volume of tissue coverage. Because all of the transducers are triggered simultaneously, sufficiently high energy can be delivered into the mid dermis during 1 pulse to increase tissue temperatures to 60 to 70°C. These temperatures cause immediate collagen contraction, followed by neocollagenesis, neolastogenesis, and tissue remodeling.

A thermal heat map of the skin during treatment is demonstrated in Figure 3. This shows epidermal cooling and a well-defined zone of high temperatures underneath that can produce controlled tissue coagulation and subsequent tissue remodeling. Targeting this depth can treat fine lines and wrinkles while avoiding damage to both more superficial and deeper structures.

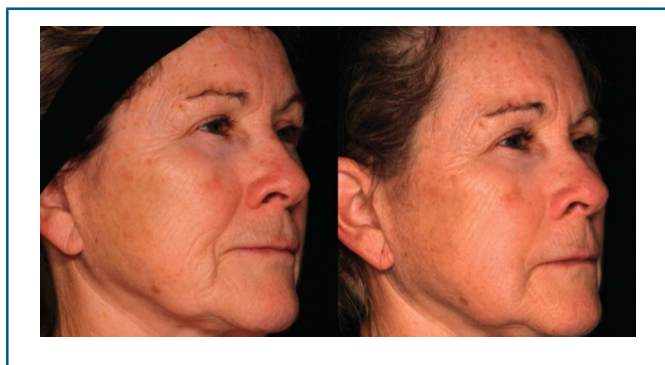

**Figure 2.** Drawing demonstrating an array of volumetric, cylindrical-shaped thermal zones that lie parallel to the skin surface.



An advanced cooling system (SofCool technology, Sofwave, Yokneam, Israel) is built into the handpiece to maintain a high level of patient safety. Because the contact cooling system is included in the handpiece, it is always in direct contact with the skin surface when triggered. The device is feedback controlled to ensure protection of the epidermis and confinement of the thermal zones to the targeted areas. The handpiece, with its 7 parallel transducers, is applied directly to the skin surface covered with a thin layer of ultrasound coupling gel to actively and evenly cool the entire treatment area and protect the epidermis. During this study, no device-related adverse events were experienced by subjects and only expected transient effects from treatment were observed, which further supports the device's strong safety features.

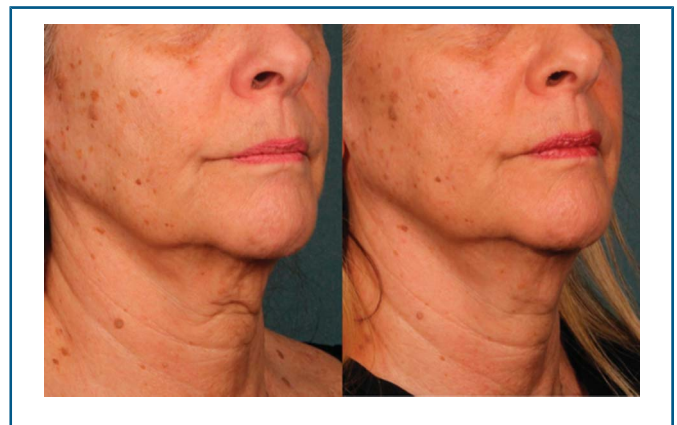These data demonstrate that treatment with high-intensity, high-frequency, parallel ultrasound beams improves fine lines and wrinkles of the face and neck (Figures 4–6). Both investigators and subjects rated improved clinical outcomes at 12 weeks after the treatment session.



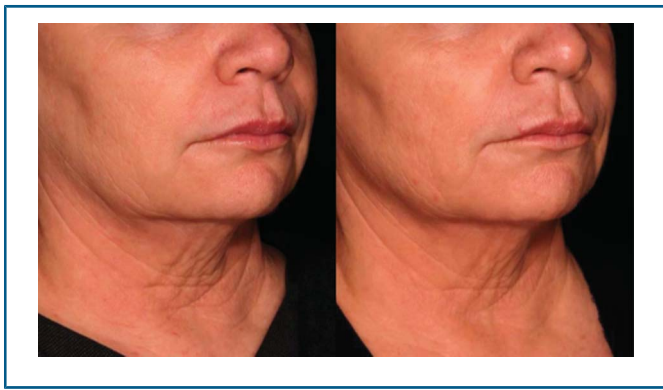**Figure 4.** Photographs of female subject at baseline (left) and follow-up at 12 weeks (right).

In addition, the 2 blinded and independent reviewers consistently selected the correct post-treatment photograph and also rated an overall clinical improvement in wrinkle score. It is interesting to note that no subject was rated by investigators to clinically worsen during the duration of the study. For the single patient who subjectively rated their wrinkles to worsen, both blinded reviewers were in agreement in correctly identifying their post-treatment photograph.

Although this study is limited by each subject having only a single treatment, these data suggest that this novel ultrasound device that uses high-intensity, high-frequency, parallel ultrasound beams can improve wrinkles and fine lines of the face and neck. Because only one treatment was performed in this study, it is possible that additional treatment sessions would produce further clinical improvement and greater subject satisfaction. Future clinical trials should include multiple treatments to more accurately



**Figure 5.** Photographs of female subject at baseline (left) and follow-up at 12 weeks (right).



**Figure 6.** Photographs of female subject at baseline (left) and follow-up at 12 weeks (right).

replicate current real-world clinical practice. This study was also limited by pain control that included topical anesthesia for 45 minutes and optional intramuscular ketorolac. In real-world practice, the authors typically offer 1 hour for topical anesthesia and include optional inhaled nitrous oxide, which has shown to control patient discomfort. Computerized measurements and imaging can also be incorporated, which can offer objective measurements of changes in skin laxity.

## References

1. Cui H, Kong Y, Zhang H. Oxidative stress, mitochondrial dysfunction, and aging. *J Signal Transduct* 2012;2012:646354.
2. Nkengne A, Bertin C. Aging and facial changes—documenting clinical signs, part 1: clinical changes of the aging face. *Skinmed* 2013;11:281–6.
3. Tobin DJ. Introduction to skin aging. *J Tissue Viability* 2017;26:37–46.
4. Mokos ZB, Ćurković D, Kostović K, Ćeović R. Facial changes in the mature patient. *Clin Dermatol* 2018;36:152–8.
5. Rabe JH, Mamelak AJ, McElgunn PJ, Morison WL, et al. Photoaging: mechanisms and repair. *J Am Acad Dermatol* 2006;55:1–19.
6. Kwan KR, Kolansky Z, Abittan BJ, Farberg AS, et al. Skin tightening. *Cutis* 2020;106:134–7.
7. Greene RM, Green JB. Skin tightening technologies. *Facial Plast Surg* 2014;30:62–7.
8. Pritzker RN, Robinson DM. Updates in noninvasive and minimally invasive skin tightening. *Semin Cutan Med Surg* 2014;33:182–7.
9. Pritzker RN, Hamilton HK, Dover JS. Comparison of different technologies for noninvasive skin tightening. *J Cosmet Dermatol* 2014;13:315–23.
10. Juhász M, Korta D, Mesinkovska NA. A review of the use of ultrasound for skin tightening, body contouring, and cellulite reduction in dermatology. *Dermatol Surg* 2018;44:949–63.
11. Fabi SG. Noninvasive skin tightening: focus on new ultrasound techniques. *Clin Cosmet Investig Dermatol* 2015;8:47–52.
12. Minkis K, Alam M. Ultrasound skin tightening. *Dermatol Clin* 2014;32:71–7.
13. Kleinerman R, Whang TB, Bard RL, Marmur ES. Ultrasound in dermatology: principles and applications. *J Am Acad Dermatol* 2012;67:478–87.
14. Kennedy JE, Ter Haar GR, Cranston D. High intensity focused ultrasound: surgery of the future? *Br J Radiol* 2003;76:590–9.
15. She WH, Cheung TT, Jenkins CR, Irwin MG. Clinical applications of high-intensity focused ultrasound. *Hong Kong Med J* 2016;22:382–92.
16. Orsi F, Arnone P, Chen W, Zhang L. High intensity focused ultrasound ablation: a new therapeutic option for solid tumors. *J Cancer Res Ther* 2010;6:414–20.
17. Haar GT, Coussios C. High intensity focused ultrasound: physical principles and devices. *Int J Hyperthermia* 2007;23:89–104.